

# Computer-Aided Navigation in Dental Implantology: 7 Years of Clinical Experience

*Rolf Ewers, MD, DMD, PhD,\* Kurt Schicho, DSc,†  
Michael Truppe, MD,‡ Rudolf Seemann,§  
Astrid Reichwein, MD, DMD,|| Michael Figl, MS, DSc,¶  
and Arne Wagner, MD, DMD#*

**Purpose:** This long-term study gives a review over 7 years of research, development, and routine clinical application of computer-aided navigation technology in dental implantology. Benefits and disadvantages of up-to-date technologies are discussed.

**Materials and Methods:** In the course of the current advancement, various hardware and software configurations are used. In the initial phase, universally applicable navigation software is adapted for implantology. Since 2001, a special software module for dental implantology is available. Preoperative planning is performed on the basis of prosthetic aspects and requirements. In clinical routine use, patient and drill positions are intraoperatively registered by means of optoelectronic tracking systems; during preclinical tests, electromagnetic trackers are also used.

**Results:** In 7 years (1995 to 2002), 55 patients with 327 dental implants were successfully positioned with computer-aided navigation technology. The mean number of implants per patient was 6 (minimum, 1; maximum, 11). No complications were observed; the preoperative planning could be exactly realized. The average expenditure of time for the preparation of a surgical intervention with navigation decreased from 2 to 3 days in the initial phase to one-half day in clinical routine use with software that is optimized for dental implantology.

**Conclusions:** The use of computer-aided navigation technology can contribute to considerable quality improvement. Preoperative planning is exactly realized and intraoperative safety is increased, because damage to nerves or neighboring teeth can be avoided.

© 2004 American Association of Oral and Maxillofacial Surgeons  
*J Oral Maxillofac Surg* 62:329-334, 2004

---

Received from University of Vienna, Vienna, Austria.

\*Professor and Head of Department, University Hospital of Cranio-Maxillofacial and Oral Surgery, Medical School.

†Scientist, University Hospital of Cranio-Maxillofacial and Oral Surgery, Medical School.

‡Scientist, University Hospital of Cranio-Maxillofacial and Oral Surgery, Medical School.

§Research Assistant, University Hospital of Cranio-Maxillofacial and Oral Surgery, Medical School.

||Surgeon, University Hospital of Cranio-Maxillofacial and Oral Surgery, Medical School.

¶Scientist, Department of Biomedical Engineering and Physics.

#Professor, University Hospital of Cranio-Maxillofacial and Oral Surgery, Medical School.

This work was financially supported by the Austrian Science Foundation FWF (grant P-12489 Med).

Address correspondence and reprint requests to Dr Schicho: University Hospital of Cranio-Maxillofacial and Oral Surgery, Medical School, University of Vienna, Währinger Gürtel 18-20, 1090 Vienna, Austria; e-mail: kurt.schicho@utanet.at

© 2004 American Association of Oral and Maxillofacial Surgeons

0278-2391/04/6203-0014\$30.00/0

doi:10.1016/j.joms.2003.08.017

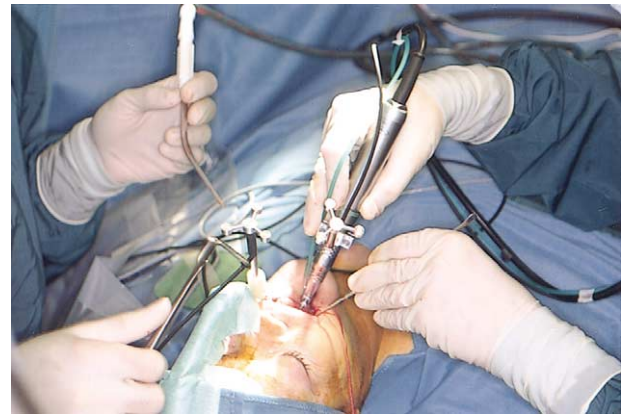
Computer-assisted navigation systems are widespread in neurosurgery, orthopedics, and ear, nose, and throat surgery.<sup>1-3</sup> In the field of oral and maxillofacial surgery, navigation technology is particularly applied with success in arthroscopy of the temporomandibular joint, in the surgical treatment of posttraumatic deformities of the zygomatic bone, in orthognathic surgery, and for distractions, osteotomies, tumor surgery, punctures, biopsies, and removal of foreign bodies.<sup>4-12</sup> Currently, a clear trend in the use of computer-assisted navigation in dental implantology can be observed. For research purposes and for use by commercial companies, navigation systems are developed that provide hardware and software developed to position dental implants. A substantial advantage of navigation is precise preoperative planning, which is optimized by taking into consideration prosthetic and functional aspects. This is of crucial importance to avoid an unfavorable mechanical load, which can lead to peri-implant bone atrophy and thus an early loss of implants.<sup>13</sup> Furthermore, navigation systems improve intraoperative safety, because damage to critical anatomic structures such as nerves or neighboring teeth can be avoided.<sup>14-16</sup> The accuracy attainable with computer-aided navigation systems has been examined in several studies and found to be sufficient.<sup>14,15</sup> For example, Wagner et al<sup>15</sup> report, in an analysis of 32 endosseous implants positioned with navigation guidance, a mean deviation of 1.1 mm together at the tip and base of the implants in lingual and vestibular direction.

Navigation can be applied with partially as well as completely edentulous patients. By means of teleconsultation via Internet remote experts can be involved in the planning phase in difficult and complex cases.<sup>17,18</sup>

At the University Hospital of Cranio-Maxillofacial and Oral Surgery in Vienna, dental implants have been positioned using computer-assisted navigation since 1995. In this period substantial improvements in hardware and software were achieved.<sup>19-22</sup> This study summarizes these experiences, presents the results of accompanying quality control, and describes the expenditure of time for preparation and execution of a navigated implant placement according to the newest technique.

## Materials and Methods

The hardware used for computer-assisted navigation technology in dental implantology is comparable with technical setups usually known from other areas of application. Implementation of dental drills and appropriate handpieces is managed by means of specially constructed tool-learning devices (also called "calibration stations"). At first, for intraoperative position registration (of patient and drill) in the context



**FIGURE 1.** Operating room site: active optoelectronic sensors (prototypes) with light-emitting diodes. The sensor attached to the patient is visible on the left and the sensor affixed to the handpiece of the drill is on the right.

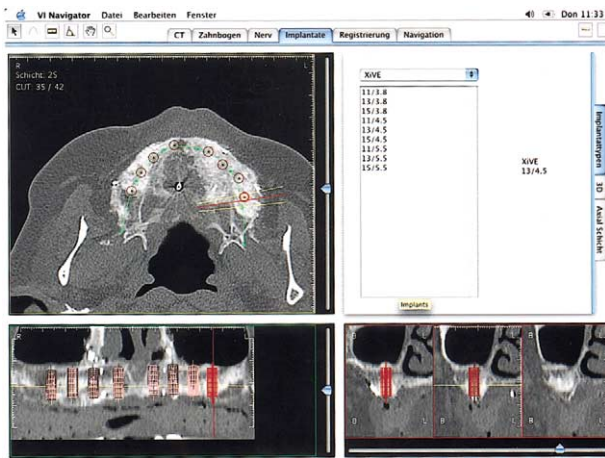
of preclinical tests as well as in routine intraoperative application, both optoelectronic and electromagnetic tracking systems are used during the 7-year study period. Starting from 1999, exclusively optoelectronic systems are applied. The following tracking systems are used in this study:

- Optoelectronic
  - ProReflex Motion Capture MCU240 (Qualisys Medical AB, Göteborg, Sweden)
  - Polaris (NDI Northern Digital Inc, Ontario, Canada)
  - FlashPoint 5000 3D Localizer (Image Guided Technologies Inc, Boulder, CO)
- Electromagnetic
  - Polhemus IsotraccII (Polhemus Inc, Colchester, VT)
  - Aurora (NDI Northern Digital Inc)

Both active and passive tools are used. An example of the frequently used active optical sensors at the operating room site is shown in Figure 1. The computer hardware used in the initial phase of routine clinical application is as follows:

- Apple (Cupertino, CA) Macintosh Power PC and later versions, according to the current level of development
- Starting from 2001 exclusively: Apple PowerMac G3 and G4 workstations and an SGI O2 RS12000 workstation (SGI, Mountain View, CA)

First, the flexible and universally applicable software package MedScanII (Artma Medical Technologies AG, Vienna, Austria) is used; since 2001, the software module Virtual Implant (Artma Medical Technologies AG, Vienna, Austria), a package espe-



**FIGURE 2.** Preoperative planning of implant positions and orientations in the maxilla with the Virtual Implant navigator. Implants are listed and sorted according to manufacturer and dimension (diameter and length), positioned by “drag and drop” with the mouse, and aligned according to prosthetic requirements.

cially developed for dental implantology, has been available. Alternatively, the software VISIT (a modular surgical planning and navigation system for computer-aided surgery, developed by W. Birkfellner and colleagues at the Department of Biomedical Engineering and Physics, Vienna General Hospital) is used. Although all Artma software products are running on Apple computers, VISIT is written for the SGI workstation. The work flow within the optimized software environment consists of the following steps:

1. Importing of CT data
2. Drawing of the dental arc and the inferior alveolar nerve (in case of interventions in the mandible)

3. Planning of implant positions and orientations in arbitrarily selected 3-dimensional views
4. Patient’s registration (by means of a splint or with microscrews directly fixed at the bone)
5. Intraoperative navigation

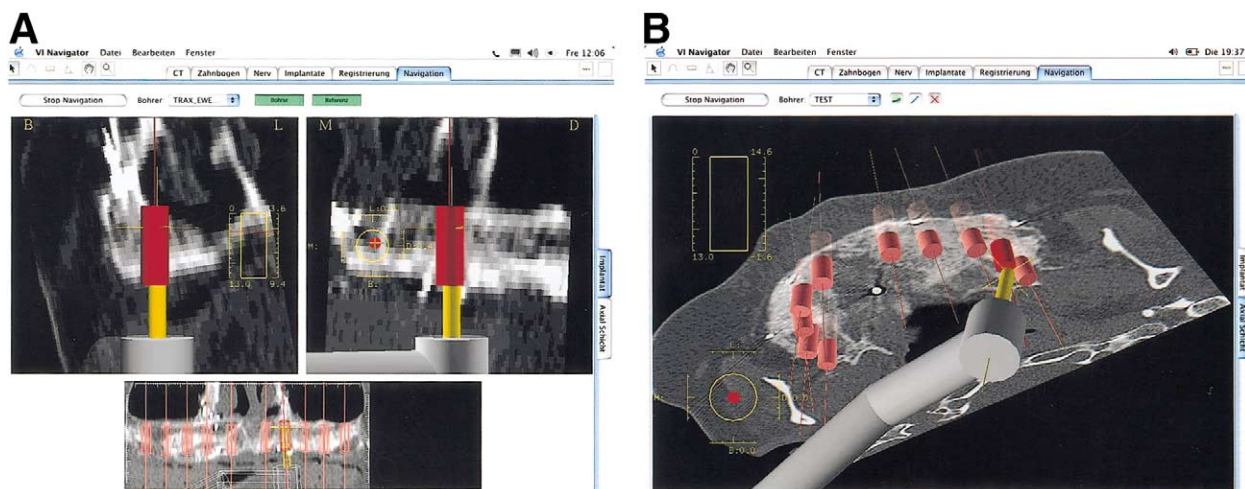
The preoperative planning can be intraoperatively modified at any step of the intervention. Figures 2 and 3 show the planning and intraoperative screens of the Virtual Implant navigator.

To evaluate the entire intervention, postoperative control CT scans are compared with the corresponding preoperative plans and examined regarding positions and angular orientations of the implants. Furthermore, the expenditure of time necessary for preparation and execution of navigation is registered.

### Results

In the period between 1995 and 2002, 55 patients with 327 dental implants were successfully positioned by means of computer-assisted navigation technology. The mean number of implants per patient was 6 (minimum, 1 implant per patient; maximum, 11 implants per patient). No intraoperative complications occurred. Postoperative assessment of the implants showed that the prosthetic requirements were fulfilled due to the accurate realization of preoperative planning. No “sleeping implants” were observed. Table 1 and Figure 4 summarize the temporal distribution of all operations over the years from 1995 to 2002.

Typical results of a postoperative evaluation of position and angular orientation of implants according to prosthetic aspects are presented in Figures 5 to 7.



**FIGURE 3.** A, B, Screens of intraoperative navigation. Within arbitrarily selected 3-dimensional views, the current drill position is visualized relative to the planned implant position. Spiderlines facilitate the finding of implant positions and the adjustment of their orientation (“angulation”). This example shows an intervention at the maxilla.

**Table 1. NUMBER OF NAVIGATED OPERATIONS AND POSITIONED IMPLANTS IN 1995 TO 2002**

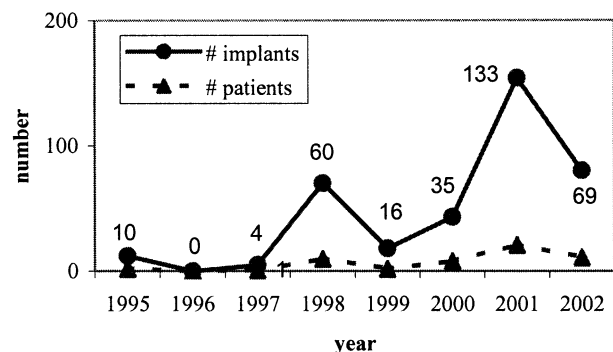
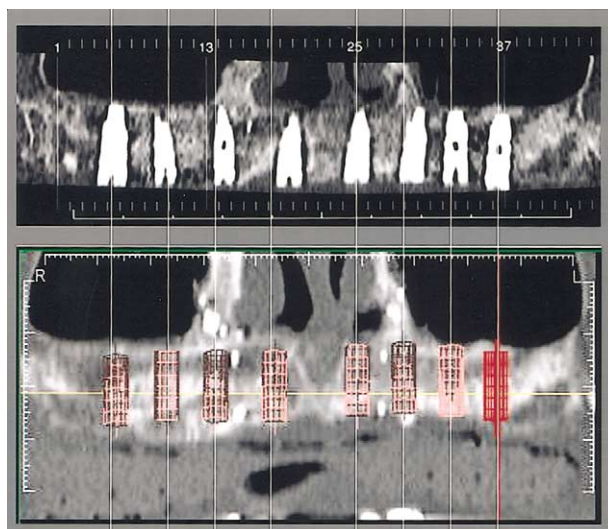
Year	No. of Operations	No. of Implants
1995	2	10
1996	0	0
1997	1	4
1998	10	60
1999	2	16
2000	8	35
2001	21	133
2002	11	69

The precision and reliability of navigation also permit the safe drilling of implants close to the nerve (lateral bypass), as depicted by Figures 8 and 9.

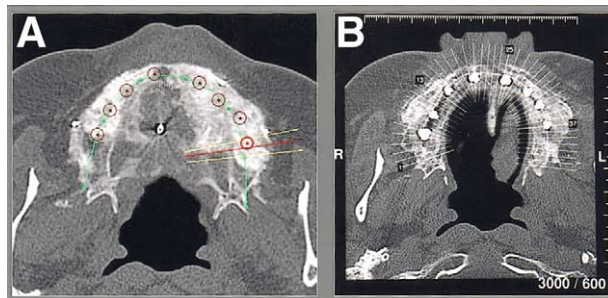
The expenditure of time for the preparation of navigated operations significantly decreased during the period from 1995 to 2002. Between 1995 and 2000, a decrease in the average total preparation duration (including positioning of the markers, CT scanning, planning, sterilization and routine control of the trackers, setup of the navigation system) from 2 to 3 days in the initial phase of clinical application (1995 to 1997) to 1 day (1998 to 2000) was observed. Starting from the end of 2000, software modules optimized for dental implantology were available. Since then, the average preparation time per operation could be reduced to one-half day, particularly because of the substantially simplified planning process.

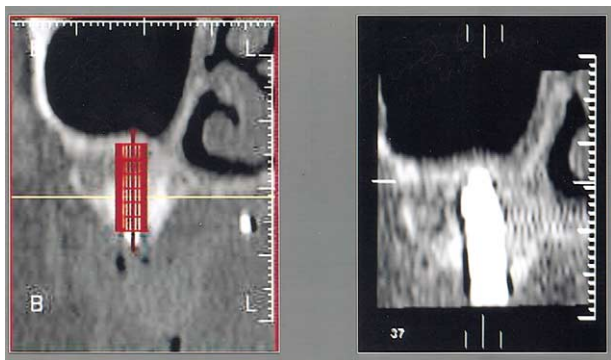
## Discussion

The experiences of a period of 7 years (covered by this study), during which a total of 55 patients were operated on successfully with computer-assisted navigation technology and 327 dental implants were positioned, show the suitability of navigation for routine

**Patients and Implants 1995-2002****FIGURE 4.** Graph depicts the number of patients and positioned implants in the years 1995 to 2002.**FIGURE 5.** Postoperative assessment of implants according to prosthetic aspects: postoperative control computed tomography scan (top) and preoperative planning (bottom) show a high degree of correspondence.

clinical application. This applies equally to cases with few implants as to patients with many (up to 11) implants inserted. Although the pros and cons of navigation in dental implantology are often controversially discussed,<sup>23</sup> navigation enables realization of the preoperative planning, which is performed taking into consideration prosthetic aspects, with high accuracy and intraoperative safety. Postoperative evaluation of the interventions resulted in exact correspondence of the actual positions and orientations of the implants with the preoperative planning. An algorithm for checking intraoperative accuracy and registration errors is integrated into the navigation software and ensures a prompt detection of possibly occurring system errors. Because planning and intraoperative navigation are based on CT data on 3-dimensional computer models that are calculated from CT data, high-quality CT scans are a fundamental prerequisite to apply surgical navigation technology. Achieving an accurate registration (ie, a reliable connection between patient and corresponding computer

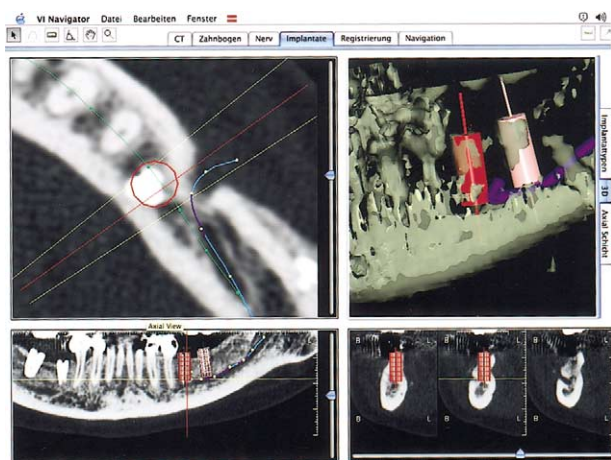
**FIGURE 6.** Preoperative planning (A) and postoperative result (B) correspond in the axial view.



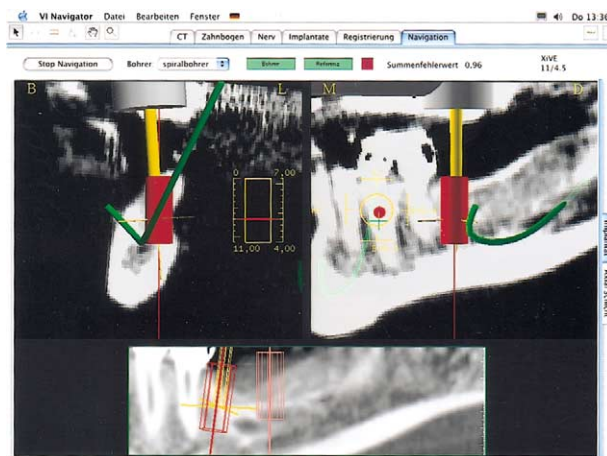**FIGURE 7.** Evaluation of realization of the planning at a single implant (left, preoperative plan; right, postoperative control computed tomography scan).

model), a careful positioning of the marker points (fiducial marker) used for registration, and the avoidance of head motion of the patient during CT scanning, which can cause shifts in the CT dataset, is essential.

During the 7 years reviewed in this study, both occlusal splints and microscrews directly affixed to the patient were used. Although the “splint method” might seem to be less invasive, after our experience, we recommend microscrews in most cases, because this method allows for a still more reliable registration and eliminates one source of error in the entire work flow (ie, in contrast to the splint, no “shifts” of microscrews can occur). Future software developments could extend the registration by a surface matching algorithm, as available in other applications. Thus, registration would be done on the basis of anatomic landmarks and structures on the patient’s skin surface. However, with respect to accuracy and reliability, at the present, registration via fiducial marker is clearly superior. Surface matching can be an addi-



**FIGURE 8.** Planning of a lateral bypass at the mandible: the inferior alveolar nerve is clearly recognizable. For safety reasons, it has to be drawn manually.



**FIGURE 9.** Intraoperative screen: lateral bypass at the mandible. Precise and reliable navigation enables safe drilling close to the nerve.

tional procedure to verify the registration and (due to the large number of points integrated in the algorithm) to improve total accuracy. Mucous membrane-carried splints (without additional rigid fixation to the jaw) were found to be completely insufficient for registration in our tests.

For navigation technology in dental implantology, basically both optoelectronic and electromagnetic tracking systems can be used intraoperatively to record positions and motions of the patient and the drill. Nevertheless, in the routine application, optoelectronic systems became generally accepted at present, offering sufficient accuracy and stability (in the sense of failure security).

A considerable disadvantage in the introduction phase of navigation in routine clinical application was the preparation time for each intervention, but the expenditure of time could be clearly reduced by 2 factors: 1) by optimized software for dental implantology (in use since the end of 2000) and 2) by a learning curve observed in the personnel who were preparing the navigations. After adequate training, hardly any errors (eg, with the preparation of the splint or the positioning of microscrews) occur. Handling of the software, both planning and navigation module, is quite easy due to a logical, self-explanatory menu structure and can be learned within a short time. A further aspect with the use of computer-aided navigation technology in dental implantology is the associated automatic and complete electronic documentation of the intervention (“flight recorder” function). This can likewise be used for patient consultation and in medical education.

Future progress is to be expected, particularly through an intensified use of teleconsultation for the planning of implants. Presently available technologies allow for a transfer of planning data via the Internet. Thus, it is possible to cooperate with experts in cen-

ters of excellence (interactive teleconsultation) or even to perform the entire planning process telemedically.

Computer-aided navigation in dental implantology is a promising technology, already successfully tested in routine clinical application, that can substantially contribute to an increase in quality and intraoperative safety for the insertion of implants.

## References

- Kelly PJ: State of the art and future directions of minimally invasive stereotactic neurosurgery. *Cancer Control* 2:287, 1995
- Freysinger W, Gunkel AR, Pototschnig C, et al: New Developments in 3D Endonasal and Frontobasal Endoscopic Sinus Surgery. Paris, France, Kugler Publications, 1995
- Thumfart WF, Freysinger W, Gunkel AR, et al: 3D image-guided surgery on the example of the 5,300-year-old Innsbruck Ice-man. *Acta Otolaryngol* 117:131, 1997
- Wagner A, Undt G, Watzinger F, et al: Principles of computer-assisted arthroscopy of the temporomandibular joint with optoelectronic tracking technology. *Oral Surg Oral Med Oral Pathol Oral Radiol Endod* 92:30, 2001
- Watzinger F, Wanschitz F, et al: Computer-aided surgery in distraction osteogenesis of the maxilla and mandible. *Int J Oral Maxillofac Surg* 28:171, 1999
- Watzinger F, Wanschitz F, Wagner A, et al: Computer-aided navigation in secondary reconstruction of post-traumatic deformities of the zygoma. *J Craniomaxillofac Surg* 25:198, 1997
- Siessegger M, Mischkowski RA, Schneider BT, et al: Image guided surgical navigation for removal of foreign bodies in the head and neck. *J Craniomaxillofac Surg* 29:321, 2001
- Enislidis G, Wagner A, Ploder O, et al: Computed intraoperative navigation guidance—a preliminary report on a new technique. *Br J Oral Maxillofac Surg* 35:271, 1997
- Wagner A, Ploder O, Enislidis G, et al: Image-guided surgery. *Int J Oral Maxillofac Surg* 25:147, 1996
- Wagner A, Ploder O, Enislidis G, et al: Virtual image guided navigation in tumor surgery — technical innovation. *J Craniomaxillofac Surg* 23:271, 1995
- Wagner A, Rasse M, Millesi W, et al: Virtual reality for orthognathic surgery: The augmented reality environment concept. *J Oral Maxillofac Surg* 55:456, 1997
- Watzinger F, Birkfellner W, Wanschitz F, et al: Placement of endosteal implants in the zygoma after maxillectomy: A cadaver study using surgical navigation. *Plast Reconstr Surg* 107:659, 2001
- Hobkirk JA, Havthoulas TK: The influence of mandibular deformation, implant numbers, and loading position on detected forces in abutments supporting fixed implant superstructures. *J Prosthet Dent* 80:169, 1998
- Birkfellner W, Solar P, Gahleitner A, et al: In-vitro assessment of a registration protocol for image guided implant dentistry. *Clin Oral Implants Res* 12:69, 2001
- Wagner A, Wanschitz F, Birkfellner W, et al: Computer-aided placement of endosseous oral implants in patients after ablative tumour surgery: Assessment of accuracy. *Clin Oral Implants Res* 14:340, 2003
- Siessegger M, Schneider BT, Mischkowski RA, et al: Use of an image-guided navigation system in dental implant surgery in anatomically complex operation sites. *J Craniomaxillofac Surg* 29:276, 2001
- Schicho K, Ewers R: Teleconsultation and 3D-visualisation in computer-assisted implantology: The current state of development (in German). *Implantologie Journal* 5:86, 2001
- Wagner A, Millesi W, Watzinger F, et al: Clinical experience with interactive teleconsultation and teleassistance in craniomaxillofacial surgical procedures. *J Oral Maxillofac Surg* 57:1413, 1999
- Ploder O, Wagner A, Enislidis G, et al: Computer-assisted intraoperative visualization of dental implants. *Augmented reality in medicine. Radiologe* 35:569, 1995
- Wanschitz F, Birkfellner W, Figl M, et al: Computer-enhanced stereoscopic vision in a head-mounted display for oral implant surgery. *Clin Oral Implants Res* 13:610, 2002
- Wanschitz F, Birkfellner W, Watzinger F, et al: Evaluation of accuracy of computer-aided intraoperative positioning of endosseous oral implants in the edentulous mandible. *Clin Oral Implants Res* 13:59, 2002
- Watzinger F, Birkfellner W, Wanschitz F, et al: Positioning of dental implants using computer-aided navigation and an optical tracking system: Case report and presentation of a new method. *J Craniomaxillofac Surg* 27:77, 1999
- Schicho K, Wagner A, Ewers R: Computer aided navigation and interactive teleconsultation in dental implantology, *in* Lemke HU, Vannier MW, Inamura K, et al (eds): *Computer Assisted Radiology and Surgery*. Berlin Heidelberg, Germany, Springer Verlag, p 975